



# Use of bisphosphonate to manage avulsion fracture of tibial tuberosity with underlying angiomatosis: A case report

**JWK Wong, DKH Yip, JKF Kong, EP Chien**

Department of Orthopaedics & Traumatology, The University of Hong Kong, Queen Mary Hospital, Pokfulam, Hong Kong

**TWH Shek**

Department of Pathology, The University of Hong Kong, Queen Mary Hospital, Pokfulam, Hong Kong

---

## ABSTRACT

An unusual case of avulsion fracture of the tibial tuberosity with underlying angiomatosis in a middle-aged man is described, with particular emphasis on the successful use of bisphosphonate in its treatment and the value of serial dual energy X-ray absorptiometry in its subsequent disease monitoring. This case illustrates the importance of careful correlation of the clinical, radiological, and histological findings in the management of skeletal tumour and tumour-like lesions. The differential diagnosis of osteolysis with vascular ectasia is discussed.

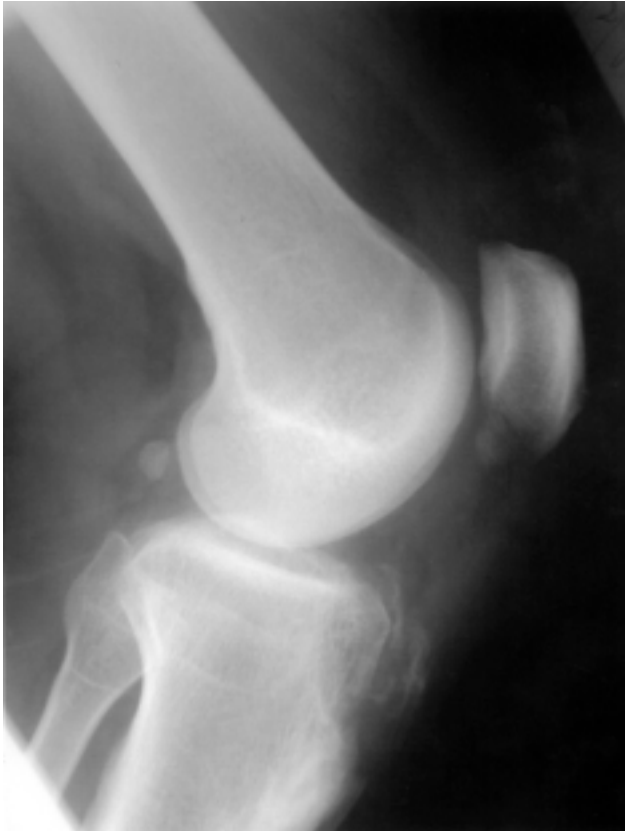**Key words:** *angiomatosis of bone; avulsion fracture; bisphosphonate; densitometry, X-ray; tibial tuberosity*

---

## CASE REPORT

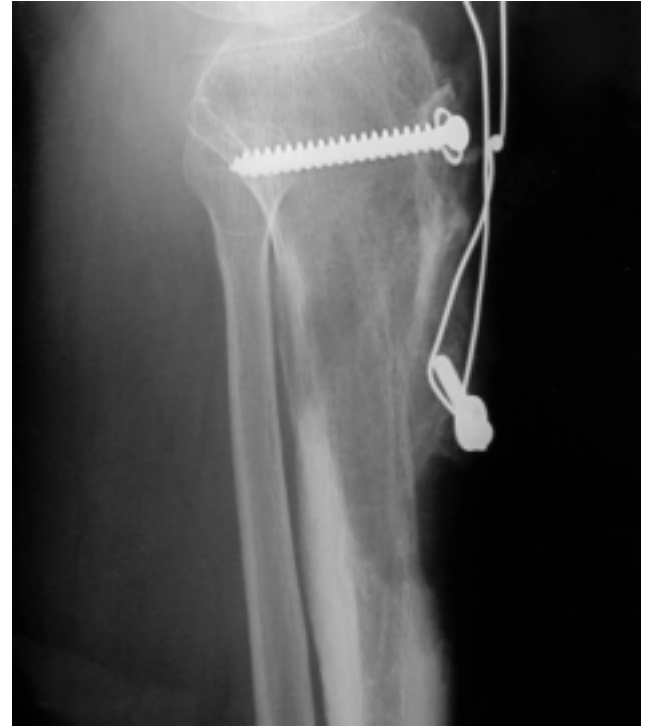A 53-year-old Chinese man had an avulsion fracture of the left tibial tuberosity that occurred while walking downstairs (Fig. 1). The fracture was initially treated with open reduction, bone grafting, and screw fixation. Bone biopsy results, performed at the same setting, were initially interpreted as being compatible with Paget's disease owing to the presence of irregular cement lines. The fracture site united after 3 months but the surrounding osteolysis did not resolve. The patient was therefore treated with a nasal preparation of calcitonin for 8 weeks. The disease progressed and the patient was referred to the Department of Orthopaedics & Traumatology, Queen Mary Hospital.

Investigations were performed to detect a possible bone tumour in the left proximal tibia. Plain X-rays showed areas of osteolysis at the proximal tibia, but did not have the characteristic features of Paget's

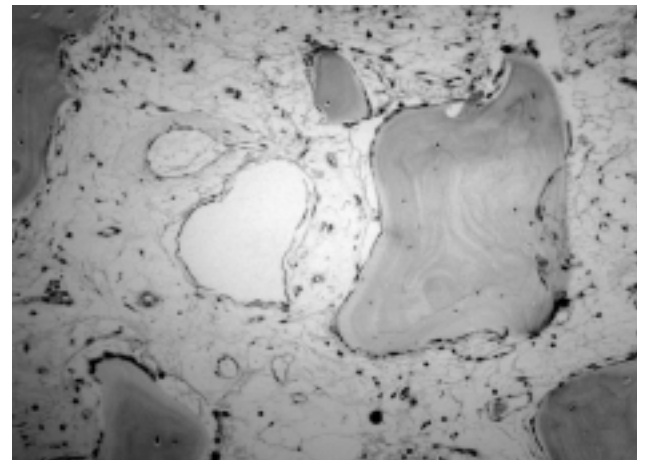


**Figure 1** Lateral X-ray of the left knee, showing avulsion of tibial tubercle.

disease, such as bowing or advancing radiolucent wedge (Fig. 2). Bone scanning showed a focal area of diffuse increased activity around the left tibial lesion, including the patella and femur. Serum alkaline phosphatase, calcium, and phosphate levels were normal. Lactate dehydrogenase levels were marginally raised. The 24-hour urine examination showed a marginally raised hydroxyproline level of 444  $\mu\text{mol}/\text{dl}$  (normal range, 120–320  $\mu\text{mol}/\text{dl}$ ). A second biopsy showed the presence of irregular dilated vessels with an associated decrease in bone trabeculae. No osteoclastic activity or prominent cement lines were visible. The histological findings were thus not typical of Paget's disease and were more indicative of a vascular lesion (Fig. 3). In the light of the histological findings and the isolated bone involvement, the lesion was identified to be an unusual form of skeletal angiomatosis that involved one single osseous site, with associated osteolysis. Further progression of the osteolysis was evident during the observation period, and a course of palmidronate was used in an attempt to halt the disease process. The patient was given 60 mg intravenous infusion of palmidronate over one hour. He was also given supplement of calcium carbonate

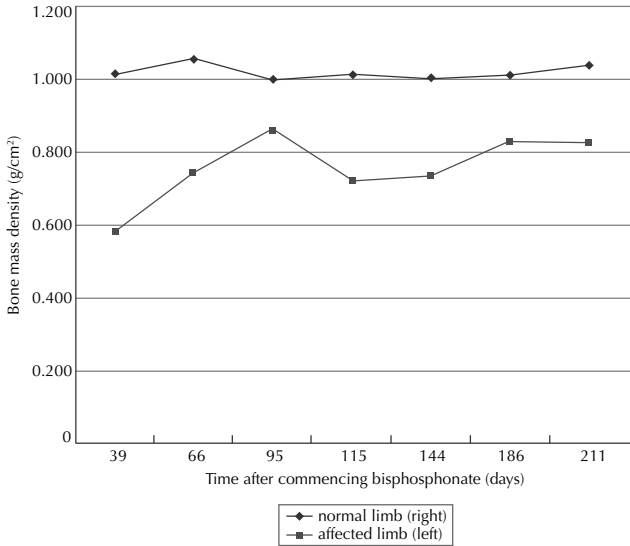


**Figure 2** Lateral X-ray when patient first presented.



**Figure 3** Photomicrograph of bone biopsy (high-power field, H&E,  $\times 50$ ) showing dilated vascular channels replacing the intertrabecular space.

1250 mg and calcitriol 0.5  $\mu\text{g}$  once daily for 6 months to maximise calcium absorption. The palmidronate infusion was repeated monthly for 6 months. Radiotherapy was not given. Progress was monitored by clinical symptoms and plain X-rays. Because of the possible risk of reavulsion of the tibial tubercle, the patient was allowed to walk only with toe touch down and assistance of crutches, during palmidronate treatment, and with a hinged knee brace.



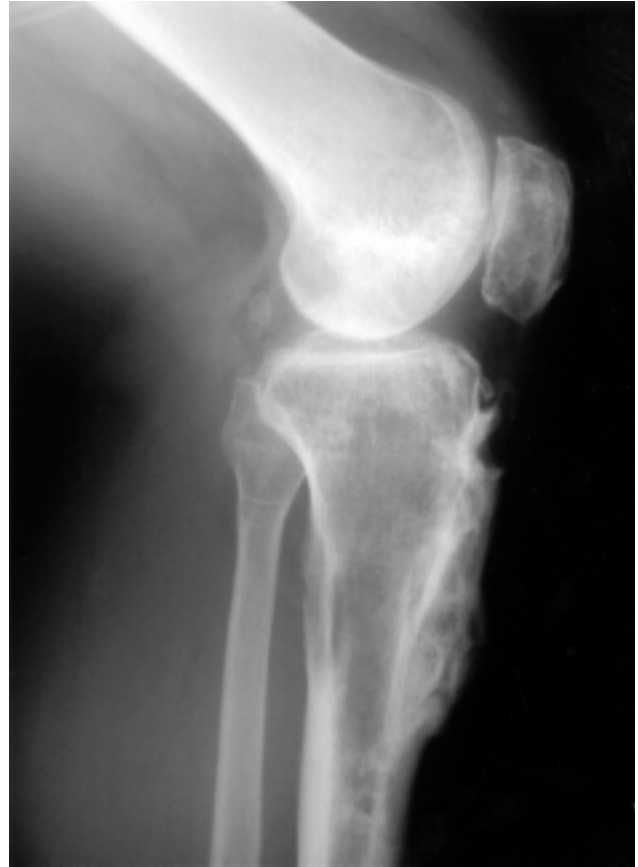**Figure 4** Mean bone mass density profile of affected (left) limb versus normal (right) limb.

As a time lag was expected for conventional X-rays to document new bone formation, bone densitometry (dual energy X-ray absorptiometry [DEXA]) technique was used to document the healing process and the bone mineral density changes during treatment with bisphosphonate (QDR 4500; Hologic Inc., Waltham, United States). The affected knee showed a definite increase in bone density after pamidronate treatment was commenced. The rate of increase of the bone density was uniform and peaked at the same time period for the different sampling areas. There was a subsequent decrease in the density, followed by another increase (Fig. 4). There were no such changes on the normal side, and there was no increase in bone density of the unaffected bone.

By one year after treatment, there was complete resolution of symptoms, return of full range of motion to the knee, and radiological consolidation of the tibia and static DEXA parameters for 6 months (Fig. 5). We thus recommended that the original screws be removed and a biopsy of the healed area be repeated. Histological investigation showed morphologically normal cortical and cancellous bone with no conspicuous osteoblastic or osteoclastic activity. The cement lines were not prominent and no vascular component was visible. The patient remained well and symptom-free at 3 years since treatment.

## DISCUSSION

Spontaneous avulsion fracture of the tibial tuberosity in adults is uncommon and, in this case, occurred in



**Figure 5** Lateral X-ray at 3-year follow-up showing good formation of bone at the affected site.

bone with underlying angiomatosis. Making the diagnosis in this case was challenging. The initial histology was very limited and showed certain histological features of Paget's disease. However, the radiological features, biochemical findings, clinical presentation, and its subsequent clinical course were most unusual features of Paget's disease. Furthermore, Paget's disease is extremely rare among the Chinese population.<sup>1</sup>

Massive osteolysis has been reported under numerous different names since it was first mentioned in the English literature in 1838.<sup>2</sup> Its clinical and pathological features were first clearly described in 1954 by Gorham et al.<sup>3,4</sup> Hence, it is often called Gorham's disease. The largest series in the literature consisted of only 7 cases.<sup>5</sup> The rarity of this condition means that no single centre can develop any extensive experience of this condition. It is therefore important that new methods of treatment be shared and the experience collectively gathered albeit at a slow pace. The diagnosis of such a rare disease is often delayed and is made only with a high index of suspicion and exclusion of other diseases. Some investigators of this

disease<sup>6</sup> suggested including criteria such as positive biopsy results for angiomatosis; absence of cellular atypia; minimal osteoblastic response; evidence of local progressive osseous resorption; nonulcerative lesion; absence of visceral involvement; osteolytic radiographic pattern; negative hereditary, metabolic, and infectious aetiology, to make the diagnosis of Gorham's disease. Using these criteria, this case is consistent with the diagnosis of Gorham's disease, or at least a mild variant of it.

Gorham's disease is a rare condition and may present as a pathological fracture. The pathological process is not well known, but it has been postulated to relate to the underlying vascular abnormality.<sup>7</sup> There are sporadic reports of treatment using radiotherapy,<sup>8</sup> but it is also known that the condition can be self-limiting.<sup>9</sup> The difficulty is knowing which cases will and which will not be self-limiting. Magnetic resonance image features, triple-phase radionuclide bone scan results, and thallium scan results have been reported by Livesley et al.<sup>10</sup> However, they provide very little useful practical information, except perhaps to confirm the mono-ostotic nature of the disease. They cannot document the intensity of the disease nor the degree of response of the bone.

Some studies suggest that osteolysis in Gorham's disease is possibly a local disturbance of osteoclastic activity.<sup>11,12</sup> Bisphosphonate may be an alternative form of treatment,<sup>12</sup> and experience with this drug in metastatic breast cancer supports its anti-osteoclastic property.<sup>13</sup> Empirical use of pamidronate infusion in the patient in this case led to a satisfactory outcome, al-

though the exact mechanism of bisphosphonate in the management of Gorham's disease remained unclear.

Conventional fracture treatment alone was unsuccessful in this case. Bisphosphonate was useful in the treatment of osteolysis and we were able to monitor the clinical course by serial DEXA examination. However, bisphosphonate was not needed for the whole course of the disease. We thus postulate that once bisphosphonate somehow temporarily halts the osteolytic process, then the normal bone response sets in. It was reassuring to observe that the normal bone was not affected by the drug. There is always a worry that generalised osteosclerosis may lead to stress fractures elsewhere. The bone density of the affected limb clearly showed a uniform response rate to bisphosphonate treatment. This combination of radiological and DEXA monitoring helped the patient to ambulate with full weightbearing after 6 months' treatment. After DEXA showed a plateau of improvement of bone density, we then removed the implants to maximise the potential of the final remodelling phase.

In conclusion, we have reported an unusual case of monostotic angiomatosis of the tibial tuberosity presenting with avulsion fracture and osteolysis, which showed a good response to empirical bisphosphonate treatment. The clinical course and radiological and histological findings indicate that this was probably a mild variant case of massive osteolysis (Gorham's disease). We have also demonstrated the value of sequential follow-up using DEXA for patients with osteolysis.

## REFERENCES

1. Wang CL, Wu CT, Chien CR, Hang YH. Paget's disease of the tibia. *J Formos Med Assoc* 1999;98:444-7.
2. Jackson JB. A boneless arm. *Boston Med Surg J* 1838;10:368-9.
3. Gorham LW, Wright AW, Shultz HH, Maxon FC. Disappearing bones: a rare form of massive osteolysis. *Am J Med* 1954;17:674-82.
4. Gorham LW, Stout AP. Massive osteolysis (acute spontaneous absorption of bone, phantom bone, disappearing bone): its relation to haemangiomas. *J Bone Joint Surg Am* 1955;37:985-1004.
5. Cannon SR. Massive osteolysis. A review of seven cases. *J Bone Joint Surg Br* 1986;68:24-8.
6. Heffez L, Doku HC, Carter BL, Feeney JE. Perspectives on massive osteolysis. Report of a case and review of the literature. *Oral Surg Oral Med Oral Pathol* 1983;55:331-43.
7. Huvos AG. Bone tumours: diagnosis, treatment and prognosis. 2nd ed. Philadelphia, PA: Saunders; 1991.
8. Dunbar SF, Rosenberg A, Mankin H, Rosenthal D, Suit HD. Gorham's massive osteolysis: the role of radiation therapy and a review of the literature. *Int J Radiat Oncol Biol Phys* 1993;26:491-7.
9. Campbell J, Almond HG, Johnson R. Massive osteolysis of the humerus with spontaneous recovery. *J Bone Joint Surg Br* 1975;57:238-40.
10. Livesley PJ, Saifuddin A, Webb PJ, Mitchell N, Ramani P. Gorham's disease of the spine. *Skeletal Radiol* 1996;25:403-5.
11. Dickson GR, Mollan RA, Carr KE. Cytochemical localization of alkaline and acid phosphatase in human vanishing bone disease. *Histochemistry* 1987;87:569-72.
12. Green HD, Mollica AJ, Karuza AS. Gorham's disease: a literature review and case reports. *J Foot Ankle Surg* 1995;34:435-41.
13. Diel IJ, Solomayer EF, Costa SD, Gollan C, Goerner R, Wallwiener D, et al. Reduction in new metastases in breast cancer with adjuvant clodronate treatment. *N Engl J Med* 1998;339:357-63.